

Surgeries Performed

Clavicle Fracture

Introduction:

Clavicle fractures are one of the most common fractures seen in the emergency department. They occur due to fall on outstretched hands, sports injuries and road traffic accidents.

[Read more](#)

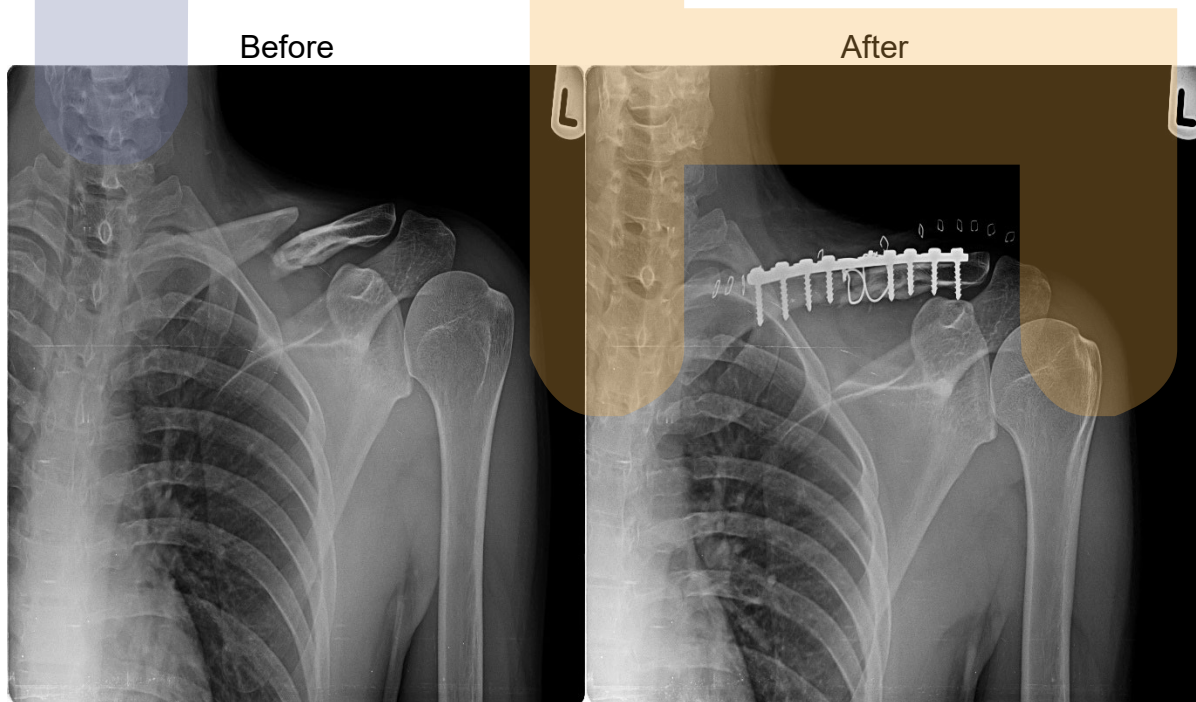
Treatment methods

Non-surgical management

Non-surgical management - in the form of arm sling, medications, physical therapy. Patients who are treated this way, usually require three weeks of immobilization followed by shoulder mobilisation exercise. Shoulder strengthening exercises are started from 3 months.

Surgical treatment

Surgical treatment - indicated in patients with tenting of skin over the fracture site, open fractures, nonunion and if the neurovascular deficit is present. The surgical treatment is in the form of plate fixation and immediate mobilization of the shoulder joint.



This gentleman had a type I open comminuted clavicle fracture treated with debridement, open reduction and plating of left clavicle. Fracture healed in 4 months follow up.

OUTCOME- Immediately after surgery

